

## Two Port Laparoscopic Cholecystectomy- A Simplified And Safe Technique

Ranendra Hajong, Arup J Baruah, Debobratna Hajong,  
Narang Naku and Girish Sharma.

This file should provide

- a. The type of manuscript: original article,
- b. Title of the manuscript: two port laparoscopic cholecystectomy- a simplified and safe technique,
- c. Running title: simplified two port laparoscopic cholecystectomy,
- d. Names of all authors/ contributors (with their highest academic degrees, designation and affiliations): Ranendra Hajong, associate professor, general surgery, NEIGRIHMS, Arup J Baruah, associate professor, general surgery, NEIGRIHMS, Debobratna Hajong, senior resident doctor, general surgery, NEIGRIHMS, Narang Naku, senior resident doctor, general surgery, NEIGRIHMS and Girish Sharma, junior resident doctor, general surgery, NEIGRIHMS.
- e. Name(s) of department(s) and/ or institution(s) to which the work should be credited: Department of general surgery, NEIGRIHMS, Shillong, Meghalaya, India.
- f. The total number of pages: 6, total number of photographs: 4 and word counts for abstract: 220 and for the text: 1050.
- g. Source(s) of support in the form of grants, equipment, drugs, or all of these: None.
- h. Acknowledgement, if any: None.
- i. Conflicts of Interest of each author/ contributor: None to declare.
- j. The name, address, e-mail, and telephone number of the corresponding author, who is responsible for communicating with the other authors about revisions and final approval of the proofs, if that information is not included on the manuscript itself: Dr Ranendra Hajong, Department of general surgery, NEIGRIHMS, Shillong, Meghalaya, India-793018, ranenhajong@gmail.com, +91-9436705149.

---

### **Abstract:**

**Context:** Cholecystectomy is the most commonly performed operation by general surgeons worldwide and the lesser invasive technique i.e. the laparoscopic cholecystectomy is the preferred operative technique both for the patient as well as for the surgeon. Conventionally laparoscopic cholecystectomy is performed by using three or four ports of various sizes. As cosmesis is an important aspect of laparoscopic cholecystectomy, the trend is now towards use of lesser ports thereby resulting in better cosmesis for patients. Surgeons are now routinely performing laparoscopic cholecystectomy by SILS (Single Incision Laparoscopic Surgery). Two ports laparoscopic cholecystectomy also gives good cosmetic result without any added risk to the patients and can be done with the conventional instruments with good patient satisfaction.

**Aims:** To study the feasibility of performing a modified technique of laparoscopic cholecystectomy by using two ports only.

**Settings and Design:** Prospective experimental type of study.

**Methods and Material:** Thirty patients with gallstone disease admitted in the hospital were included in the study after obtaining proper informed consent.

**Results:** None of the cases had to be converted to open procedure or any added ports were required. The average operation time was  $35 \pm 5$  minutes. The average hospital stay was one day. No patients developed any post-operative complications till 6 months post-operatively.

**Conclusions:** The two port laparoscopic cholecystectomy that is being described here is a safe and simple procedure with good patient satisfaction.

**Key words:** Laparoscopic cholecystectomy; two ports; simplified technique.

---

### I. Introduction

Surgery is the treatment of choice in symptomatic gallstone disease and is also recommended in asymptomatic patients due to complications followed by stone release in common bile duct [1-5]. Laparoscopic cholecystectomy is the gold standard [6]. This operation is conventionally performed by using four ports into the abdomen, one for the camera, two for manipulation of tissues and another for retraction [6]. Two-port laparoscopic cholecystectomy is a newer modification, and has been reported in the international literature to be

safe and feasible [7]. The technique that is being described here is a simple one and can be performed safely with good patient satisfaction.

## **II. Materials and Methods**

A total of thirty patients with symptomatic gallstone disease were included in the study. Informed consent was obtained from all the patients. Ethical clearance was obtained from Institute Ethics Committee. Simple descriptive statistics was used.

Inclusion criteria:

- i. Patients with ASA class I& II admitted for routine laparoscopic cholecystectomy 18 – 60 years of age.

Exclusion criteria:

- i. Patients with ASA III and above.
- ii. Patients admitted for gallbladder disease with acute symptomatology.
- iii. Patients with suspected or proven malignancy of gallbladder.
- iv. Patients with deranged bleeding parameters.
- v. Patients not willing for laparoscopic cholecystectomy,
- vi. Patients below 18 years and above 60 years.
- vii. Patients with proven or suspected common bile duct stones.
- viii. History of jaundice.
- ix. History of gallstone pancreatitis.
- x. Obese patients with BMI > 35.

For objective assessment of patient satisfaction, the following questionnaires were used. Patients were asked the questions before discharge from the hospital:

1. Are you happy with the procedure?
  - a. Yes,
  - b. No.
2. Would you advise the same procedure to your known persons?
  - a. Yes,
  - b. No.
3. On a scale of ten how much point would you give?

Score of 8-10: Very satisfied.

Score of 6-7: Satisfied.

Score of  $\leq 5$ : Not satisfied.

The patient was laid supine with head end and the right side of the patient tilted 15° up. The two ports used for access to peritoneal cavity (Fig. 1) included a 10 mm supra-umbilical port (for camera) and another 10 mm epigastric port (for dissection). The gallbladder was manipulated through strategically placed two traction sutures. One was placed higher up in the right hypochondrium in the anterior axillary line through the ninth intercostal space, and passed through the fundus of gall bladder. It was fixed by tying a knot. The other traction suture was placed in right flank at a lower level to hold neck of the gall bladder; and the same suture was brought out around the mid-clavicular line just below the tip of ninth costal cartilage (Fig. 2). This suture was kept free to adjust the level of traction required during different steps of the procedure. If anterior dissection was required, then the right flank end of the suture was pulled by keeping the other end of the suture fixed with an artery forceps. Whereas for performing posterior dissection, the right flank end of the suture was kept steady and traction was applied on the right hypochondrial end of the suture. 1-0 silk sutures were used for tractions. Figure 3 showing the gall bladder being dissected from liver bed after clipping the cystic duct and Figure 4 showing the cosmesis after the end of the procedure.

## **III. Results**

The operation was performed successfully in all the thirty patients without conversion to open surgery in any of the patients. The mean duration of surgery was 35 minutes  $\pm$  5 SD. No complications were noted in any patient during follow-up till six months after surgery. No pneumothorax was observed in any of the patients. Patients were allowed oral feeds 6 hours after surgery and discharged from the hospital the next day of surgery. The patients were satisfied with the cosmetic outcome after the surgery with a satisfaction score of 7 and above in all the patients.

## **IV. Discussion**

In the new era of minimal access surgery, the preferred outcomes under consideration are not only the safety, but also quality, which is often defined by pain and cosmetic results. Scar-less surgery is the ultimate goal for both, surgeons and the patients. Minimal invasive surgical techniques continue to evolve. As

technology and instrumentation continue to improve, so are the complexities of operations that can be performed in a minimal invasive way [8].

Two-port laparoscopic cholecystectomy has shown a higher patient's satisfaction score [9]. However, whether it offers any additional advantages remains controversial [7]. A report on two-port laparoscopic cholecystectomy has already shown that all patients would choose this technique over four-port approach, as the postoperative pain is significantly reduced and the procedure is cosmetically more acceptable to the patients [10].

Two- port laparoscopic cholecystectomy has been reported to be safe and feasible, but it is technically difficult even in expert hands because of limited operative field [11].

The laparoscopic surgeons are developing and using a number of different techniques all over the world. Ng WT described laparoscopic cholecystectomy using a single, supra-umbilical incision; however, the single wound is, in fact, merely the result of combining the camera and adjacent 10-mm working ports [12]. Lee KW reported a two-port needle-sopic cholecystectomy using 2-mm or 3-mm endo- graspers [13].

Tagaya N et al reported a new technique of laparoscopic cholecystectomy by two-port approach using abdominal wall lifting method [14]. They noticed that retraction of the gallbladder is possible by the insertion of forceps through the umbilical port along the telescope which might eliminate the necessity of creating the third port.

Kagaya developed a "Twin-port" system that allows a 5-mm camera and a forceps to be inserted through a single port. A 5-mm trocar is inserted approximately one cm below the xiphoid process, and the laparoscopic cholecystectomy is performed via two ports [15].

In the present study, the conventional 30 ° camera was used. Retraction of gall bladder either for anterior or posterior dissection did not pose any problem in any of the patients and all the operations were performed safely and without any undue delay with good patient satisfaction.

## V. Conclusions

The two port laparoscopic cholecystectomy that is being described here is a safe and simple procedure and can be performed by not so experienced surgeons in laparoscopic surgery. The patient satisfaction is quite good and there is no added risk to the patients. So the above mentioned technique can be used as an alternative to single incision laparoscopic surgery in developing and underdeveloped countries and specially surgeons working in rural areas.

## References

- [1]. Sakorafas GH, Milingos D, Peros G. Asymptomatic cholelithiasis: is cholecystectomy really needed? A critical reappraisal 15 years after the introduction of laparoscopic cholecystectomy. *Dig Dis Sci*2007; 52: 1313-1325
- [2]. Freitas ML, Bell RL, Duffy AJ. Choledocholithiasis: evolving standards for diagnosis and management. *World J Gastroenterol* 2006; 12: 3162-3167
- [3]. Martin DJ, Vernon DR, Toouli J. Surgical versus endoscopic treatment of bile duct stones. *Cochrane Database Syst Rev* 2006; CD003327
- [4]. Slanetz PJ, Boland GW, Mueller PR. Imaging and interventional radiology in laparoscopic injuries to the gallbladder and biliary system. *Radiology* 1996; 201: 595-603
- [5]. Portincasa P, Moschetta A, Petruzzelli M, Palasciano G, Di Ciaula A, Pezzolla A. Gallstone disease: Symptoms and diagnosis of gallbladder stones. *Best Pract Res Clin Gastroenterol* 2006; 20: 1017-1029
- [6]. Ramachandran CS, Arora V. Two-port laparoscopic cholecystectomy: an innovative new method for gall bladder removal. *J Laparoendosc Adv Surg Tech* 1998;8: 303-8.
- [7]. Poon C M, Chan KW, Lee DWH, Chan KC, Ko CW, Cheung HY, Lee KW. Two-port vs four-port laparoscopic cholecystectomy: A prospective randomized controlled trial. *Surg Endosc* 2003;17:1624-27
- [8]. Kroh M, Rosenblatt S. Single-port, laparoscopic cholecystectomy and inguinal hernia repair: First clinical report of a new device. *J Laparoendosc Adv Surg Tech* 2009;19:215-7
- [9]. Poon CM, Chan KW, Lee DWH, Chan KC, Ko CW, Cheung HY, Lee KW. A two-port laparoscopic cholecystectomy: initial results of a modified technique. *J Laparoendosc Adv Surg Tech* 2002;12:259-62.
- [10]. Leung KF, Lee KW, Cheung TY, Leung LC, Lau KW. Laparoscopic cholecystectomy: two- port technique. *Endoscopy* 1996;28:505-7
- [11]. S H Waqar, M A Zahid. Two- port laparoscopic cholecystectomy: an early experience. *Journal of Surgery Pakistan (International)*. Oct- Dec 2009; 14(4): 179-181.
- [12]. Ng WT, Kong CK, Wong YT. One-wound laparoscopic cholecystectomy. *Br J Surg* 1997; 84: 1627.
- [13]. Lee KW, Poon CM, Leung KF, Lee DWH, Ko CW. Two-port needlescopic cholecystectomy: prospective study in 100 cases. *Hong Kong Med J* 2005;11:30-5
- [14]. Tagaya N, Fukutomi K, Kogure H. New two port technique for laparoscopic cholecystectomy: A preliminary report. *Dokkyo J Med Sci* 1999;26:419-22
- [15]. Kagaya T. Laparoscopic cholecystectomy via two ports using the "Twin-port" system" *J Hepatobiliary Pancreat Surg* 2001;8:76-80

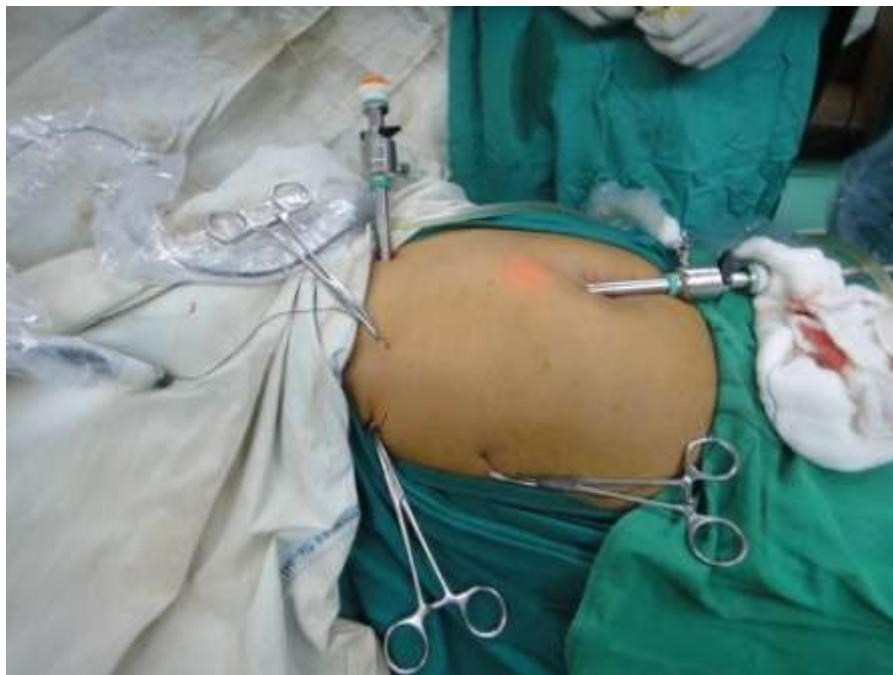

Figure 1 showing trocar and traction suture positions

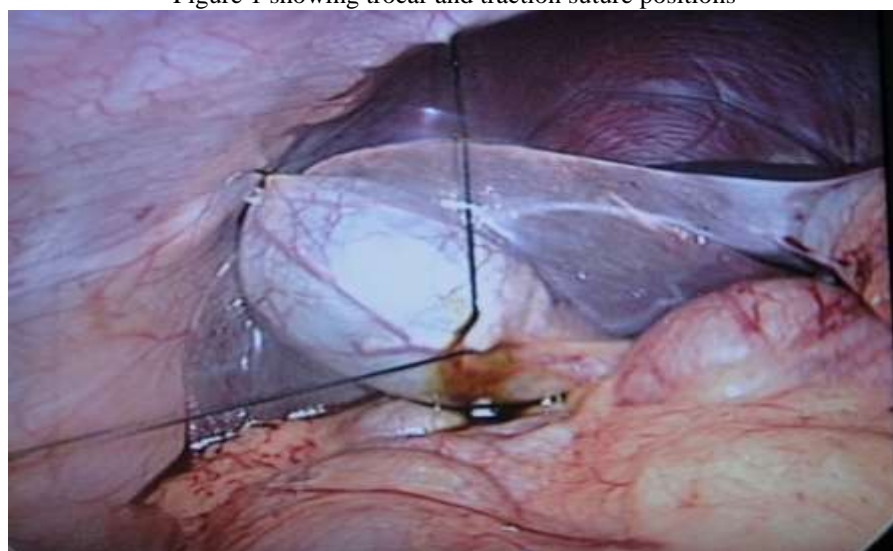


Figure 2 showing traction suture positions from inside

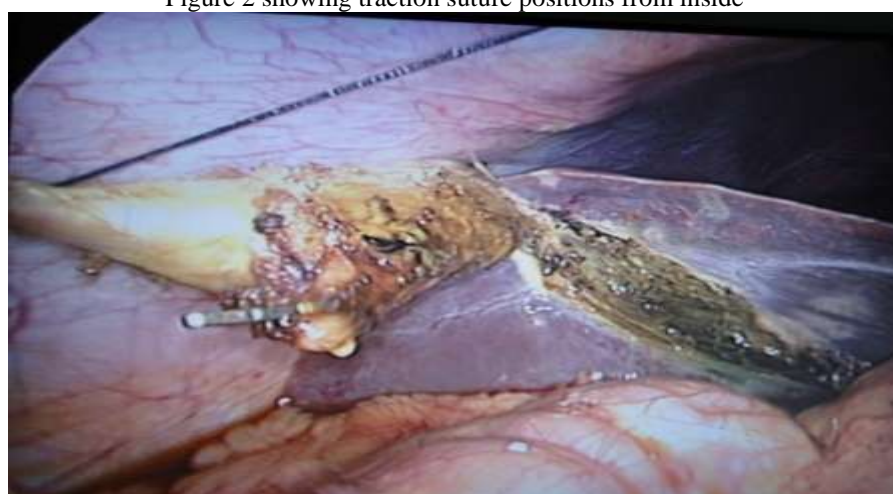

Figure 3 showing gallbladder being dissected from liver

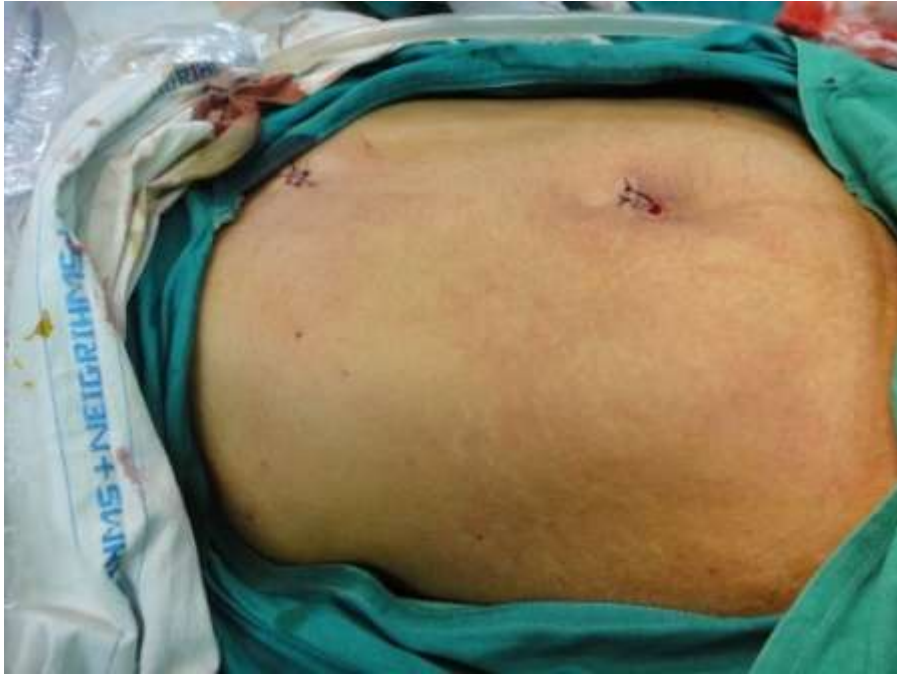

Figure 4 showing postoperative cosmesis.